CORPUS PUBLISHERS

Corpus Journal of Case Reports (CJCR)

Volume 3 Issue 1, 2022

Article Information

Received date : February 14, 2022

Published date: February 27, 2022

*Corresponding author

Marvin do Nascimento, Department of Materials Science, Military Engineering Institute, Rio de Janeiro, RJ, Brazil.

Keywords

Dental Fracture; Dental Implants; Immediate Loading; Autogenous Graft

Case Report

Rehabilitation in Immediate Load of the Central Element with Autogenous Graft: A 7-Year Follow-Up

Marvin do Nascimento*, Bruno Martins de Souza

Biomaterials Laboratory, Department of Materials Science, Military Engineering Institute, Rio de Janeiro, RJ, Brazil.

Abstract

A 42-year-old female patient who had a fracture in her right upper central incisor with indication of tooth extraction, followed by rehabilitation with dental implant and autogenous graft with posterior provisionalization. After rehabilitation and follow-up after seven years, it can be highlighted that good planning relating the properties of somatized implants to the individual patient's properties can promote good success of osseointegrated implants.

Introduction

Dental fractures in anterior teeth directly compromise the integrity of smile aesthetics. This is because the smile is identified as one of the main elements of facial contrast [1]. Thus, any interference in this region directly compromises the aesthetics, and consequently, the patient's self-esteem. Dental fractures have an incidence of up to 3% worldwide, and the most affected dental elements are the upper incisors [2]. The correct diagnosis of "how", "when" and "why" the fracture occurred is important to understand the degree and extension of the fracture. It also enables a good rehabilitation planning. In this sense, a good anamnesis and complementary exams guide a good planning construction [3]. Rehabilitation with osseointegrated implants in immediate loading promotes a safer rehabilitation, more aesthetic and with a greater longevity when compared to conventional prosthetic rehabilitations [4]. Moreover, although Brånemark's initial protocol directed two distinct stages, current studies support the single-stage technique, encompassing the concept of immediate loading in single dental implants [5].

This case report describes a female patient who had a fractured upper right central incisor with an indication for exodontia of the tooth, followed by rehabilitation with dental implant and autogenous graft with subsequent provisionalization.

Case Report

Female patient, 42 years old, seen in private practice in February 2015 with chief complaint of "pain in the front tooth after biting a pitted olive in a pie". It was reported by the patient that after the occurrence, she felt the tooth became "soft". Intraoral clinical examination revealed extensive mobility towards the lingual vestibule and redness in the region of the gingival apex (Figure 1).

Figure 1, Patient Initial Identification.

Figure 1: initial image of the patient when he arrived at the dental clinic presenting mobility and gingival pain and inflammation around tooth 11.

On radiographic examination it was observed that element 11 had an intracanal metal pin that was too thick and disproportionately short for the dimensions of the dental element. A Cone-Beam CT scan was then requested to confirm the diagnosis of root fracture, to measure whether there was any loss of buccal wall, and to assess what would be the most appropriate implant dimension for the replacement of the element. After tomographic evaluation, the diagnosis of root fracture and absence of buccal wall loss was confirmed. Therefore, we opted for the exodontia of the fractured element with immediate implant installation and provisionalization of crown for element 11. The radiographs were lost due to technical artifact.

Surgical Stage: Exodontia, Implantation and Graft

Two tubes of the anesthetic articaine 1:100,000 were used for local anesthesia (terminal infiltration technique). The remaining crown and pin (single body) were removed with an arthroplasty. After detachment with periotome of the region circumscribed to the root and slight lever movement (quinelate apex 303), a manual root extractor (WF surgical) was used (Figure 2).

Figure 2, Exodontia of the Dental Element 11.

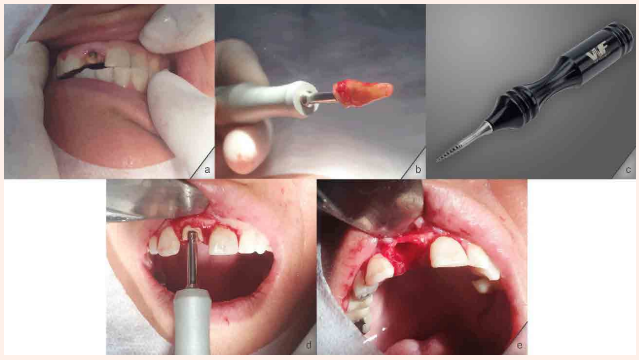

Figure 2: presentation after removal of the clinical crown. (a) clinical view of the root remnant inside the alveolus; (b) removal of the root remnant; (c) manual root extractor (WF surgical); (d) removal of the root remnant with the manual extractor; (e) empty alveolus.

After curettage of the alveolus, a Titamax ex (Neodent) 4.0x13mm External Hexagon implant was installed, following the drill sequence indicated by the manufacturer. For installation an Implantmed (W&h) motor was used at a speed of 800 rpm for milling and 30 rpm for implant installation. Furthermore, the counter angle used was Koncept 20:1 (Kavo) (Figure 3).

Figure 3, Titanium Implant Installation

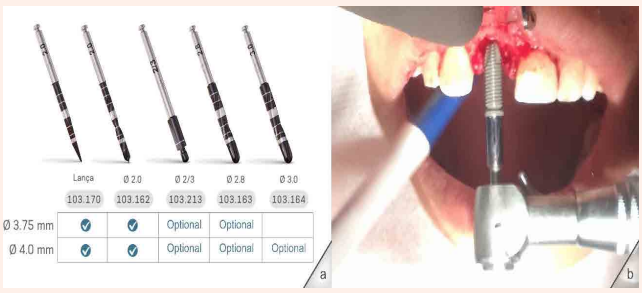

Figure 3: (a) size of implantation drills according to manufacturer; (b) implant insertion.

For this case, a locking of 40N/cm2 was obtained, checked by means of a manual torque meter (Neodent). After installation, we opted for the use of autogenous graft extracted from the retromolar region for insertion into the gap area between the implant and the alveolus in order to minimize bone loss resulting from the procedure. To perform the autogenous graft extraction technique of the retromolar region, the region was duly anesthetized (malamed technique) with articaine 1:100,000, an incision was made with a 15c scalpel blade (solidor), for graft harvesting, a premium bone collector drill (wf surgical) was used at a speed of 1200rpm. The collected material was hydrated with saline solution and inserted into the element 11 gap (Figure 4).

Figure 4, Bone Graft Collection and Application

Figure 4: grafting collection in the posterior region of the mandible and application of the bone graft. (a) identification of the region and predictable anesthesia; (b) access for graft removal; (c) premium bone collector drill (wf surgical); (d) appearance after bone collection; (e) preparation of the bone graft in saline solution; (f) application of the graft in the anterior region of the mandible in dental element 11.

Prosthetic Stage: Fabrication of the Provisional

For provisionalization was used a plastic ucla 4.1 (neodent) and neotorque screw 4.1. After insertion of the ucla, Alike resin (GC) was used around the plastic component and for finishing, and a stock tooth referring to element 11 in color A3 New Ace (Kota). For polishing the resin, the Master 3 polishing kit (DH Pro) was used. After finishing the temporary, we chose to suture the site with nylon 5.0 (shalon) suture thread (Figure 5).

Figure 5, Provisionalization.

Figure 5: preparation of the provisional. (a) insertion of the ucla; (b) adaptation and suture around; (c) provisional with stock tooth; (d) aspect after bone collection; (e) and (f) final aspect after implantation and provisionalization.

Planning Considerations

Rehabilitations with titanium implants have high success rates, especially when accompanied by good surgical planning. This immediate loading is made possible by a set of factors ranging from implant design features to bone quality [6]. These topography characteristics provide good integrity between primary (mechanical friction), secondary (osseointegration), and tertiary (functional load dissipation relationship) stability [7]. The implant used has a cylindrical design with the thread fillets arranged in a trapezoidal shape, which matches the indication for the anterior region of the maxilla (bone type III). In order to provide good primary stability, the autogenous graft was taken from the posterior region of the mandible (bone type III). This type of bone is more porous in the alveolar ridge region and more trabecular in the ridge region. It is a porous cortical and thin trabecular bone with regularly moderate medullary space. Generally, osseointegration and thus secondary stability occurs within a period of six months. Thus, different implant properties can be related to different individual patient characteristics. And this fact will guide the rehabilitation plan. For example, if the patient had periodontal disease, which is one of the main causes of implant failure, probably the planning and choice of implant, as well as its characteristics would be different from those chosen for this case [8]. In this sense, it was thought of a good "construction" of primary stability to then achieve good osseointegration. This way, the shape of the implant body added to the implant profile

satisfies the stability of the implants in a direct relation to the immediate load.

Follow-Up 7 Years Later and Final Considerations

Patient returned seven years later for evaluation and follow-up of implant integrity. This time without any complaints. Figure 6 shows the patient now seven years after rehabilitation. And Figure 7 shows the comparison of the radiographs from 2015 until now.

Figure 6, Seven Years After Implementation.

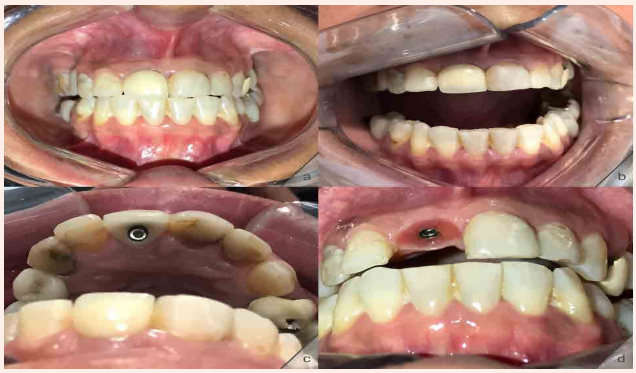

Figure 6: Clinical view seven years after surgical rehabilitation showing good relationship with adjacent tissues. (a) and (b) clinical view of the rehabilitation; (c) occlusion view of the screw-retained implant; (d) occlusion view showing the implant site without the clinical crown showing good biocompatibility and absence of any manifestation of inflammation or irritability.

Figure 7, Comparison of the Radiographs

Figure 7: Follow-up periapical radiographs. (a) immediate post in 2015; (b) follow-up one year later (2016); (c) follow-up seven years after (2022).

The technique of immediate loading has osseointegration success rates compatible with the conventional technique. Moreover, there is a conservation of bone integrity and preservation of the alveolus. The height and disposition of the supporting periodontium can be maintained. It should be noted that postoperative recovery is much more rigorous in cases of immediate loading, and especially when a graft is used, so as not to compromise the initial integrity and cause micro-movements.

Contribution

The authors also contributed to this paper.

Note

The surgery was performed by implant dentist Bruno Martins de Souza.

Conflict of Interest

We declare no competing interests.

Conclusion

In view of the factors presented, it can be concluded that a good planning for the use of osseointegratable implants is of utmost importance. Not only a planning related to the surgical or prosthetic technique, but also to the characteristics and properties of the biomaterial. Thus, the perspective to be followed is "different types of implants with different properties for different situations". This in order to achieve a good biocompatibility, longevity, and durability of the implanted biomaterial.

References

1. Giudice LG, Lipari F, Lizio A, Cervino G, Cicciù Mn (2012) Tooth fragment reattachment technique on a pluri traumatized tooth. Journal of conservative dentistry 15(1): 80-83.
2. Mazzoleni S, Graf F, Salomon E, Simionato F, Bacci C et al. (2016) Influence of Root Canal Posts on the Reattachment of Fragments to Endodontically Treated Fractured Incisors: An in vitro Experimental Comparison. Journal of esthetic and restorative dentistry 28(2): 92-101.
3. Hintz R, da Silva FR (2015) Fratura dental com tratamento multidisciplinar. Publicatio UEPG: Ciências Biológicas e da Saúde 21(2): 85-91.
4. Rodrigues ML, Costa MDM, Dietrich L (2021) Immediate load unit implants: possibility of oral and aesthetic rehabilitation – literature review. Research, Society and Development 10(11): e237101119546.
5. Batista SHB (2019) Comportamento dos tecidos moles em redor de implantes com carga imediata: revisão literária. Mestrado em Medicina Dentária, Faculdade Ciências da Saúde.
6. Elias CN, Meirelles L (2010) Improving osseointegration of dental implants. Expert review of medical devices 7(2): 241-256.
7. Elias CN, Soares FM (2021) Influências dos perfis das roscas dos implantes osseointegráveis. Full Dent. Sci 12(47): 67-74.
8. Nascimento M (2021) The Oral Microbiota Influences in the Osseointegration Process. Open Access J Dent Oral Surg 2(2): 1021.