CORPUS PUBLISHERS

Corpus Journal of Dairy and Veterinary Science (CJDVS)

Volume 2 Issue 2, 2021

Article Information

Received date : May 07, 2021

Published date: August 02, 2021

*Corresponding author

Hidaia B Zolain, Phd, Department of Anatomy, Faculty of Veterinary Science University of Nyala, Sudan

Keywords

Mesonephros; Metanephros; Ovary; Atretic Follicle; Mesovarium; Preoulatory; Follicle

Research Article

Topography and Gross Anatomy of the Ovary of the Prenatal Dromedary Camel (*Camelus Dromedrius*)

Hidaia BZ[1*] and Osman DI[2]

1Phd, Department of Anatomy, Faculty of Veterinary Science University of Nyala, Sudan

2Professor, Department of Anatomy, Faculty of Veterinary Medicine University of Khartoum, Sudan

Abstract

The aim of the present study are to investigate the time of differentiation of the foetus into a female or male, the topography of the ovary in relation to the mesonephros and metanephros, time of descent of the ovary, the gross anatomy of the ovary during the three trimesters. This study was conducted in 50 foeti of dromedary camel *Camelus dromedrius* then standard anatomical method was used to study the collected samples. The descent of the ovary began in (8 cm CVRL) about (87 days old foetus). The left mesonephros degenerated earlier than the right mesonephros while the left ovary differentiated earlier than the right ovary. The antral follicles were found only during the third trimester. The development of the ovary of the camel was similar to that of the other animal but with special characteristic of it's on.

Introduction

Camels have proven to be the unique domestic animals during severe drought periods, not only surviving such drought, but also producing and reproducing [1,2]. She camels are seasonal breeders with a relatively short breeding period during which ovarian activity is increased [3-5]. Furthermore, they are induced ovulators and therefore require coital contact for ovulation to take place [1,3,6,7]. Reproduction in domestic animals, as a major source of food and other products for human, has a great importance and study of related subjects including sex differentiation and gonadogenesis during foetal life can solve many questions on the normal development and various disorders of urogenital system (Banankhojasteh, Ranjbar, Alboghoubeish, and Rashidi, 2006). The pivotal processes in ovarian development include primordial follicle assembly which occurs prenatally .These events are essential for determining fertility in adult live [8]. Rodjers and Iraving-Rodjers [8] suggested that since the development and regression of follicles are associated with major structural and functional changes, it's important to classify follicles accurately as healthy or atretic at all stages of development. The available literature about the development of camel foetus is scanty and mainly concerned with the development of the conceptus [1]. The research concerning the development of the ovary of the camel foetus, is scanty and reported by [9-14]. The foetal ovary of camel received little attention and this may be due to the paucity of material available for investigation. Therefore this study was conducted to investigate the topography and gross anatomy of the camel ovary during prenatal life. There for this study aimed to investigate the gross anatomy of the prenatal development of the ovary.

Review of Literature

In Sow foetus, Patten (1948) mentioned that, both gonads and mullarian ducts sank progressively farther into the body cavity. In so doing, they pull with them peritoneal folds comparable to the mesenteries of intestinal tract. While these folds are stretched out, they allow the ovaries, uterine tubes and uterus to move caudally, laterally and somewhat ventrally. Foetal ovary is jointed to the mesonephros with connective tissue until approximately the crown rump length reaches 7 cm in swine, 11cm in cattle and 8.5cm in horse [15]. Thereafter, it rests in the pelvic major after the 17 cm, 21.5 cm and 27.5 cm crown rump lengths respectively [15]. Furthermore, the settlement of the ovary in horse is comparatively earlier than that in cattle and swine. Swine ovary increases gradually in weight with an increase of crown rump length, but in cattle it gradually increases only up to the 57.5 cm crown rump length [15]. However, in the horse, the ovary increases up to the 26 cm crown rump length, reaches its maximum at the 64 cm crown rump length and thereafter decreases and reaches a value similar to that reported at 33 cm curved crown rump length. The sudden increase in weight of bovine and buffalo foetal ovaries from the 8th to 10th month of gestation coincided with the development of atretic vesicular follicles and with the increase in maternal plasma follicle stimulating hormone level at that time [16]. At gestational age of 3 month, the ovaries appear as oval or spindle in shape with symmetrical thickening just cranial to the anterior end of the differentiating mullarian ducts and are attached to the caudolateral borders of the kidney. However, the final pelvic position of the ovary is reached at the end of the 6 month; the right ovary is slower in descending than the left one [16]. Human ovary is suspended by a short mesentery named mesovarium which comes into prominence as the gonad out grows mesonephros. The remains of the atrophic urogenital ridge, at more cranial levels, connect with the cranial pole of the ovary and persist as a suspensory ligament. Similarly the terminal portion of the genital ridge unites the caudal end of the ovary first to the transverse bend of the urogenital ridge, and then to the uterus which developed in it. These connections become fibromuscular and known as the proper ligament of the ovary (Arey, 1974).

Dyce, Sack and Wensing (1987) mentioned that, ovarian descend is very limited in most species, being greatest in ruminant in which the ovaries are shifted caudally to the abdomenopelvic boundary. In the mare, Dyce et al. (1987) suggested that, the ovaries descend from where they are developed initially and they commonly lie in the dorsal part of the abdomen, cranio-ventral to the iliac wings, approximately in the plane of 6th lumber vertebra. In 3 month buffalo foetus, the ovaries are located just cranial to the anterior end of the differentiated mullarian duct and are attached to the caudo-lateral borders of the kidney (Ranjbar et al., 2007). In camels, Abd El-Razik [11] stated that, the position of the ovary of the camel foetus varied according to the stage of development and the ovaries are observed first in the sublumbar region medial to the mesonephros in 5-9.5 cm curved crown rump length. On reaching the 14.5 cm curved crown rump length, they are noticed at the visceral surface of the permanent kidney. By the end of the 4th month, the ovaries are still abdominal in position lateral to the lateral border of the kidney. During the 5th month of gestation they approach the pelvic inlet and attain their final pelvic position on the 13th month

of gestation which coincided with 120 cm curved crown rump length of the foetus. Abdel Hafez [14] stated that, the size, shape and location of the ovaries of the camel foetuses varied according to the stage of the prenatal development. Abd El-Razik [11] & Abdel Hafez [14] reported that, the ovaries of camel foetus have different shapes: oval, circular or bean-shaped forms. Abdel Hafez [14] has noticed flat and irregular shapes during the late stages of pregnancy.

Ovary of the Adult

In mares, the ovaries have a bean shape and they are normally large in size and they are situated in the sub lumbar region ventral to the fourth and fifth lumbar vertebrae, while in cows the ovaries are oval in shape, pointed at the uterine end and they are usually situated near the middle of the lateral margin of the pelvic inlet (Sisson, 1975). The camel ovaries are flattened and lobulated and each one is enclosed in an ovarian bursa (Abdalla, 1965). Moreover, in the adult camel the ovary has a shape of a broad bean, 2 cm in length and 1.5 cm in width. The ovarian artery of each side originates directly from the aorta at the level of the 6th lumber vertebra approximately 3-5 cm before the origin of the external iliac artery (Ghazi, 1981). Musa [1] stated that, the ovary of camel is characteristically different from other large domestic animals and the Graafian follicle has no predilection site for development and can be detached from the ovary with the digital pressure without rupturing. The follicle is more vascular than in the other large domestic animals. Smut and Benzuidenhot [17] reported that, the ovaries of camel are suspended by the mesovarium and situated in the sublumbar region, ventral to the 6th and 7th lumber transverses processes. They have different shapes mostly oval and flattened laterally, and irregular due to their physiological stages. The ovary of camel lies within the bursa ovarica which is formed by the mesovarium medially and mesosalpinex laterally (Srikandakumar, Johnson, Mahgoub, Kadim and Al-Ajami, 2003) [5,17].

Ovaries of camels are located in the caudal part of the abdominal cavity ventral to the lumber region and enclosed in a peritoneal covering, the ovarian bursa. They are somewhat flattened and lobulated with more or less circular ovoid in outline [6]. The ovaries of camel are always found in the caudal part of the abdominal cavity. In nonpregnant animals, the ovaries are just anterior to the pelvic inlet between the 6th and the 7th lumbar vertebrae, and they are enclosed in the mesosalpenix fold, the bursa ovarica, which opens medially. The cord-like ovarian ligament is well developed and is extended from the hilus on the dorsal border of the ovary to the dorsal surface of the broad ligament (12; Osman, 2007). Skidmore and Adam [5] stated that, the camel ovary is located about 36 cm away from the opening of the vulva but the variation of their position is due to their physiological stages. In camels and ruminants, each ovary can be referenced by cranial and caudal poles as well as its dorsal and ventral surfaces (12; Samuelson, 2006). The medial and lateral surfaces are slightly convex and the colour of ovaries varied from light red to different shades of pink. According to Ali [18], a wide variation has been reported in the length, width, thickness and weight of the camel ovary.

Material and Methods

The study was conducted in 50 camel foeti at different ages of gestation period collected from different slaughter houses in Sudan, CVRL (Crown Vertebral rump length) equation Y=0.366X-23.99 which was described by ELWishy, et al. [19] was used for the determination of the foetal age (X) in days from the known (Y) curved crown rump length in centimeters. The measurement of the (CVRL) started from the point of the forehead (crown) up to the base of the tail along the dorsum of the foetus using a tape meter. The gross anatomical study was carried out in either unfixed specimens or in foetuses fixed in 10% formalin. The study included the observation of the external genitalia caudally and the position of the left and right ovaries. For determination of the topography of the left and right ovaries, the lumber muscles and some structures were removed to expose the lumbar vertebrae, to determine their relationship with uterine horns and other organs. The length, width, shape and weight of the ovaries were recorded. The topography of the ovaries in relation to the mesonephros and metanephros has received special attention.

Results

First trimester

Early stage of the first trimester

In 6 cm CVRL The mesonephros occupied a great area in the caudal part of the abdominal cavity dorsal to the right and left lobes of the liver. The metanephros was situated in the sublumbar region ventral to the level of (2-5) transverse processes of lumbar vertebrae and the free border of the metanephros was in contact with the dorsal border of mesonephros. The gonads at this stage were oval in shape and located medial to the anterior extremity of the mesonephros. The lateral surface of the gonad joined the visceral surface of the anterior extremity of the mesonephros. The gonads were in contact with to the intestine medially and liver cranially (Figure 1). In 7 cm CVRL (85 days old) foetus, the mesonephros was large and irregular in shape and occupied a great area of the caudal part of the abdominal cavity in the sublumbar region which extended from (3-7) transverse lumbar processes. Its ventral free border was in contact with the dorsal border of the liver. The metanephros didn't appear clearly when only abdominal muscles and peritoneum were removed. The whole metanephros was covered by the mesonephros laterally and ventrally and by the transverse processes of (4-6) lumbar vertebrae dorsally. The ovary at this stage was bean-shaped and situated at the level of (3-4) transverse lumbar processes and covered by the mesonephros and liver laterally and joined to the anterior extremity of mesonephros medially (Figure 2) and was in contact with the intestine by its visceral surface. The distance between the two ovaries was approximately about 0.4 cm. In 8 cm CVRL (87.4 days old) foetus, left aspect and lateral view, a narrow part from the metanephros was situated ventral to the transverse processes of (4-6) lumbar vertebrae. The mesonephros was covered ventrally by the left lobe of the liver and extended between the levels of (3-7) transverse lumbar processes. The posterior extremity of mesonephros occupied the notch of the dorsal border of the left lobe of the liver and was in contact with the iliac wing [20-25].

Figure 1: photograph of abdomeno-pelvic region in a foetus during the indifferent stage (3.2 cm CVRL, 74.3 days old) showing an elongated genital ridge (arrow) in the medial surface of the large mesonephros (MS).

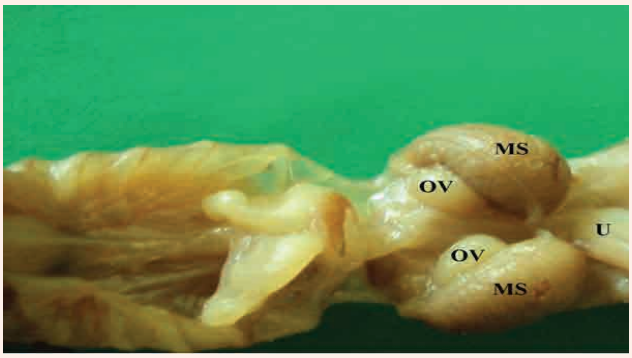

Figure 2: photograph of abdomeno-pelvic region of a female foetus during first trimester (8 cm CVRL, 87.4 days old foetus) showing the relation between the ovary (OV), the mesonephros (MS), the urachus (U) .ow) in the medial surface of the large mesonephros (MS).

At right lateral view, the metanephros was situated ventral to the level of (3-6) transverse lumbar processes while the dorsal half of the mesonephros extended from (3-7) transverse lumbar processes, and partially covered by the right lobe of the liver ventrally and laterally. At ventro-dorsal view, the metanephros was jointed ventrally to the dorsal surface of the anterior extremity of the mesonephros; the spleen was in contact

with the cranial pole of both the metanephros and ovary. The ovary was oval in shape and jointed medially to the visceral surface of the anterior extremity of the mesonephros and in contact medially and ventrally with the small intestine and dorsally with the metanephros (Figure 2). The distance between the two ovaries was about 0.4 cm and the right ovary was slightly cranial in position than the left one. In 8.4 cm CVRL (88 days old) foetus, At the left lateral view, the dorsal surface of the metanephros was in contact with the transverse lumbar processes of the (3-6) lumbar vertebrae. The ventral free border of the metanephros was jointed to the dorsal attached border of the mesonephros while the cranial pole of the metanephros was in contact with the caudal border of the spleen. The mesonephros extended between the (2-7) transverse lumbar processes and was in contact with the left lobe of the liver dorsally and laterally (Figure 2). The right metanephros was located ventral to the level of (3-6) transverse lumbar processes and was jointed to the cranial part of the attached border of the mesonephros which extended from (2-7) transverse lumbar processes.

At the ventro-dorsal aspect, the ovary appeared oval in shape and was situated medial to the mesonephros and was jointed to the visceral surface of the anterior extremity of the mesonephros and was in contact dorsally and medially with both metanephros and intestine respectively. The distance between the two ovaries was about 0.8 cm (Figure 2). In camel foetus 10 cm CVRL, about (92.9 day old foetus) the metanephros increased in size while the mesonephros decreased in size. The metanephros was still located dorsal to the mesonephros. The ovary was situated between the two types of embryonic kidneys and was jointed medial and dorsal to the cranial extremity of the mesonephros and in contact ventro-medially with the ventral free border of the metanephros [26-30]. The right ovary was situated at the level of 3rd transverse lumbar process and was in contact cranially and medially with the right lobe of the liver and ventro –medially with the jejunum. The left ovary was situated at the level of the 4th transverse lumbar process and was in contact cranially and medially with the large intestine.

Mid stage of the first trimester

In 15 cm CVRL (106.5 days old) foetus, at a left lateral aspect, the metanephros occupied the space between the levels of (2-6) transverse lumbar processes in the sublumbar region. The cranial pole of the metanephros was in contact with both the dorsal border of the spleen and dorsal border of the left lobe of the liver. The regressed mesonephros was jointed ventro-caudally to the caudal pole of the metanephros and extended between the (4-6) transverse lumbar processes. The ventral and visceral surfaces of the mesonephros were in contact with the intestine. The left ovary had circular shape and was situated ventral to the convex of the free border of the metanephros at the level about 4th transverse lumbar process and was jointed to the cranial extremity of the regressing mesonephros. At this level, the ovary was in contact with both the caudal border of the spleen, dorsal border of the liver and small intestine. The right metanephros occupied the level between (3-6) transverse lumbar processes and the free border was in contact ventrally and cranially with the right lobe of the liver which covered both the ovary and mesonephros laterally. Ventro-dorsal view showed that the distance between the two ovaries was about 1.5 cm. The uterine horn and oviduct appeared like a continuous narrow tube. In 15.3-16 cm CVRL (106.5-109 days old) female dromedary foetuses, the metanephros occupied the area dorsal to the mesonephros which became much smaller and irregular in shape and was jointed to the visceral surface of the caudal pole of the metanephros. The left ovary appeared oval in shape and occupied the region medial to the visceral surface of the metanephros at the level of (4-5) transverse lumbar vertebrae and was jointed to the anterior extremity of the mesonephros. Both ovary and mesonephros were jointed to the visceral surface of the metanephros, and were situated dorsal to the developing intestine [31-35]. The right ovary was located in the area at the level of 4th transverse lumbar process (Figure 2).

Late stage of the first trimester

In 22 cm CVRL (126 days old) female foetus, At left lateral view, the metanephros was situated ventral to the level of (3-7) transverse lumbar processes and the visceral surface was in contact with both the duodenum and pancreas medially and large intestine ventrally. The left ovary had a circular shape and situated in the sublumbar region at the level of (6-7) lumbar vertebrae and was jointed dorsally to the caudal half of the free border of the metanephros by suspensory ligament; the ovary was in contact cranially and ventrally with both the caudal border of the spleen and dorsal border of the liver respectively. At a ventro-dorsal view, the visceral surface of the ovary was in contact laterally with the umbilical artery and intestine; the regressing mesonephros didn't appear at this age in the left aspect (this result indicates that the left mesonephros was terminated earlier than the right one and the left ovary was differentiated and separated from the mesonephros earlier than the right ovary (Figure 3). At a lateral right aspect, the regressing mesonephros was jointed to the caudal pole of the developing metanephros and appeared like a small circular prominence at the caudal pole of the metanephros. The length of the right ovary ranged between 0.3 and 0.6 cm with an average of 0.43 cm, while the length of the left ovary ranged between 0.3 and 0.6 cm with an average of 0.43 cm. The width of both the right and left ovaries ranged between 0.1 and 0.4 cm with an average of 0.23 cm. In both left right ovaries the thickness ranged between 0.1 and 0.4 cm with an average of 0.23cm.

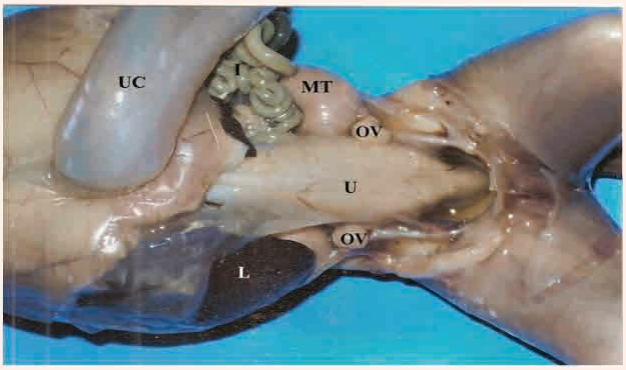

Figure 3: Photograph of the ventro-dorsal aspect of the abdomeno-pelvic region in a female foetus during the second trimester (31 cm CVRL, 150 days old foetus). Note the topography of the ovary (OV) in relation to the metanephros (MT), the urachus (U), the round ligament of the uterus (arrows), the liver (L), the small intestine (I) and the umbilical cord (UC).

Second trimester

Early stage of the second trimester

In 25 cm CVRL (134 days old) foetus, The left metanephros was situated ventral to the (3-6) transverse lumbar processes and was in contact cranially and laterally with the medial surface of the spleen. The left ovary was situated ventral to the caudal pole of the metanephros, approximately at the level of 6-7 transverse lumbar processes and was in contact ventrally with the caecum, about 0.5 cm from the caudal border of the spleen (Figure 3). The right metanephros was situated ventral to (2-6) transverse lumbar processes and the medial half of metanephros was covered cranially and laterally by the right lobe of the liver and was in contact ventrally with the small intestine. The right ovary was situated just caudal to the caudal pole of the right kidney and was in contact ventrally with the dorsal margin of the right lobe of the liver. At a ventro-dorsal aspect, the distance between the two ovaries was about 2 cm and the ovaries had a circular shape and both ovaries were situated lateral to the umbilical arteries. In 29.3 cm CVRL (145.6 days old) foetus, the metanephros occupied the area between (3-6) transverse lumbar processes and the mesonephros was completely degenerated. The left ovary had a kidney shape and was situated just caudal and in contact with the caudal pole of the metanephros dorsal to the colon, and close to the caudal extremity of the spleen. The ovaries were attached cranially to the sublumbar region by the suspensory ligament and to the uterine horns by an ovarian ligament. In 31 cm CVRL (150 days old) foetus, the opening of the vulva had an elongated inverted pear shape and covered laterally by two swollen lips of the vulva, and at the base of this opening, the clitoris appeared like small process with dorsal sharp end (Figure 3).

At lateral and right view, the metanephros occupied the sublumbar region ventral to the (3-6) transverse lumbar processes of the lumbar vertebrae and was in contact ventrally with the visceral border of the right lobe of the liver. The ovaries had a typical kidney shape and the right ovary was situated about 0.1 cm caudal to the caudal pole of the metanephros at the level between the 6th and 7th transverse lumbar processes. It was in contact ventrally with the right lobe of the liver and medially with the intestine. The left ovary occupied the caudal part of the abdominal cavity at the level of the 7th transverse lumbar process. The cranial pole of the ovary was in contacted with the caudal pole of the metanephros and the free border of the ovary was in contact ventrally with the large intestine. The distance between the ovary and the spleen was about 0.4 cm (Figure 4). At a ventro-dorsal aspect, the distance between the two ovaries was about 1.3 cm and the uterus had a Y shape. Each ovary was jointed to the uterine horn by the proper ovarian ligament and the broad ligament and to the sublumbar region by the suspensory ligament (Figure 4).

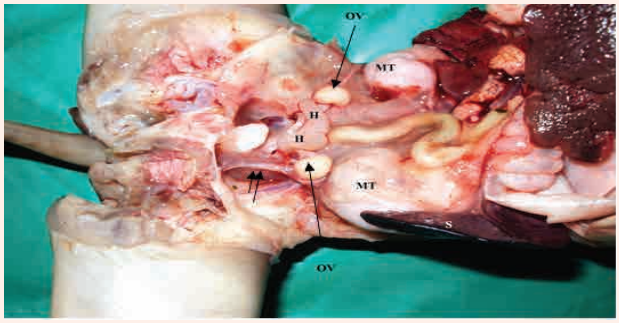

Figure 4: photograph of ventro-dorsal view of abdomeno- pelvic region of a female foetus during the second trimester (40 cm CVRL, 174.8 days old foetus). Note the position of the ovary (OV) in relation to the metanephros (MT) and the uterine horns (H), the proper ligament of the ovary (arrow), the round ligament of the uterus (double arrows).

Middle stage of the second trimester

In a female camel foetus at 39.3 cm CVRL (173 days old), The ovary had a typical kidney shape and whitish in colour. The left ovary was situated ventro-caudal to the caudal pole of the developing metanephros about 2 cm from the caudal extremity of the spleen and dorsal to the colon. The suspensory ligament of the ovary extended dorsally to the dorsal surface of both the ovary and metanephros (Figure 4). The right ovary was situated cranio-ventral to the iliac wing, about 1.3 cm caudal to the caudal pole of the right metanephros. The ventral border of the ovary was in contact with the dorsal border of the right lobe of the liver. The distance between the two ovaries was about 4 cm. Both ovaries were situated lateral to the umbilical arteries. In 40 cm CVRL (175 days old), the left metanephros occupied the area ventral to the (3-6) transverse lumbar processes and in contact ventrally and cranially with the medial surface of the dorsal border of the spleen. The left ovary was situated deep and cranio-medial to the iliac wing and lateral to the umbilical artery about 0.3 cm caudo-medial to the caudal pole of the metanephros and about 1cm from the caudal border of the spleen (Figure 4). The right metanephros occupied the area ventral to (2-6) transverse lumbar processes and was covered ventrally and cranially by the right lobe of the liver.

The right ovary was covered laterally by the caudal border of the right lobe of the liver and was situated about 0.4 cm caudal to the caudal pole of the metanephros and was in contact ventrally with the caecum. The distance between the two ovaries was about 1.8 cm, and both ovaries had typical kidney-shape and were situated lateral to the umbilical arteries and cranio-lateral to the uterine horns and were jointed to the sublumbar region by the suspensory ligament and to the uterine horns by the proper ovarian ligament and the broad ligament (Figure 5).

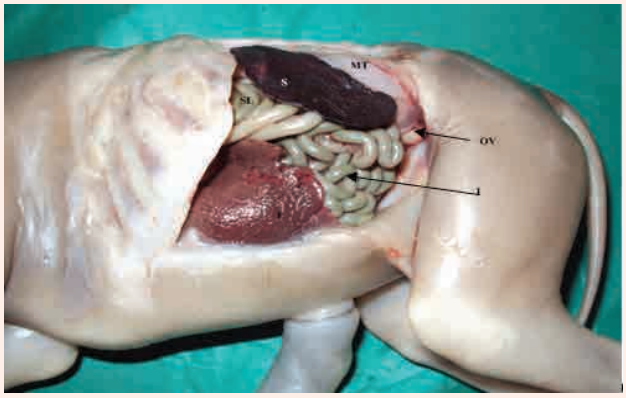

Figure 5: photograph of the left side (lateral view) of the abdomeno- pelvic region of a female foetus during the second trimester (40 cm CVRL, 174.8 days old foetus). Showing the position of the ovary (OV) in relation to the metanephros (MT), the spleen (S), the liver (L), the small intestine (I) and the spiral loop of the ascending colon (SL).

Late stage of the second trimester

In 48 cm CVRL (196.7 days old) foetus, The left metanephros was situated ventral to (3-7) transverse lumbar processes. The left ovary had a kidney shape and was found cranio-ventral to the iliac wing and was in contact with the caudal pole of the metanephros. The suspensory ligament extended dorsally to both dorsal borders of the ovary and metanephros. The right metanephros was found ventral to (3-6) transverse lumbar processes, and the cranial and lateral borders of the metanephros in contact with the right lobe of the liver. The ovary had a kidney shape and was situated caudally about 0.3 cm from the caudal pole of the metanephros, and was in contact ventrally with the duodenum. At a ventro-dorsal aspect, the uterus had a (T) shape and the distance between the two ovaries was about 3 cm and they were found lateral to the umbilical arteries. The length of both the right and left ovaries varied between 0.7 and 0.8 cm with an average of 0.75 cm [35-39]. The width of both right and left ovaries ranged between 0.3 and 0.4 cm with an average of 0.35 cm. The thickness of both the right and left ovaries was ranged between 0.3 and 0.4 cm with an average of 0.35 cm. The weight of both left and right ovary was ranged between 0.10 and 0.20 gm with a mean of 0.12 ±0.020 gm.

Third trimester

Early stage of the third trimester

In 75.5 cm CVR (271.8 days old) female foetus, The ovary had a kidney shape with reddish cortex and pale medulla .The left ovary was in contact with the ventro-caudal surface of the caudal pole of a large metanephros and was situated dorsal to the spiral loop of Ascending colon and was jointed to the well developed suspensory ovarian ligament which extended to the sublumbar region through the lateral surface of the metanephros. The ovary descended caudal to and about 2 cm from the spleen. The right ovary at this age was found about 1cm caudal to the caudal pole of the metanephros. The distance between the two ovaries was about 3.5 cm and the uterus and uterine horns were well developed and made a curvature lateral to the umbilical arteries In 76 cm CVRL (273 days old) foetus, the ovary had a kidney shape and had fissures on its surfaces; in the right ovary, the fissure extended from the surface of the ventral free border to the hilus of the ovary. The ovary was in contact ventro-medial with the metanephros and was found ventral to the iliac wing and medial to the umbilical arteries (Figure 6).

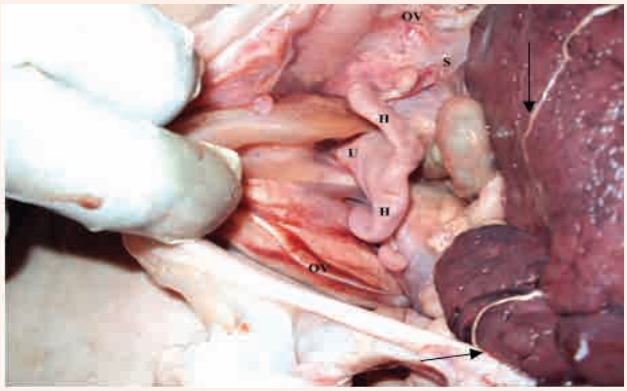

Figure 6: photograph of ventro–dorsal view in abdomeno- pelvic region of a female foetus during the third trimester (75.5 cm CVRL, 271.8 days old foetus). Note the relation between the ovary (OV), uterine horn (H) and the uterus (U), the suspensory ligament (S), the liver (L) and the proper ovarian ligament (arrow).

Middle stage of the third trimester

In 103.5 cm CVRL (348 days old) female foetus, the ovary was flattened and possessed fissures on its free surface and was found ventro-medial to the metanephros and dorsal to the urachus while the umbilical arteries were found lateral to the ovaries (Figure 6). In 104 cm CVRL (349.7 days old) foetus, the right metanephros was found ventral to the distance between the 12th rib and the 4th transverse lumbar processes and dorsal to the intestine. The right ovary had a bunch of grapes appearance and was situated about 3.7 cm caudal to the caudal pole of the metanephros, ventral to the iliac wing and medial to the umbilical artery. The left metanephros was situated ventral to the (2-6) transverse lumbar processes and was in contact ventrally with the dorsal border of the

spleen and spiral loop of the ascending colon. The left ovary was situated caudo-medial to the caudal pole of the metanephros, about 4.8 cm from the caudal border of the spleen. Moreover, the left ovary had a number of vesicular follicles bulged from its free surface (Figure 6).

Late stage of the third trimester

In 110 cm CVRL (366 days old) foetus,the left metanephros possessed shallow fissures on its surface and was situated ventral to the (3-6) transverse lumbar processes and in contact ventrally and cranially with the dorsal border of the spleen. The left ovary was not seen when the abdominal wall was excised because it was covered by the urachus (Figure 7). The right metanephros occupied the area between the level of (1-5) transverse lumbar processes and was in contact cranially with the medial surface of the right lobe of the liver, and caudally it was in contact with the distal loop of the ascending colon. Also the right ovary was not seen at this level of dissection. At a ventro-dorsal aspect, the right ovary had a triangular shape and was situated in the pelvic inlet about 4 cm caudal to the medial surface of the caudal pole of the right metanephros. The right ovary was found dorsal to the urachus, lateral to the descending colon and medial to the umbilical artery. Two small follicles bulged from the surface of the ovary. The left ovary had a flattened shape and showed small fissures on its surface and was situated about (2.7) cm from the caudal pole of the metanephros and slightly caudal in position than the right one. Both ovaries were attached to the sublumbar region by suspensory ligaments and to the uterine horns by the proper ovarian ligament and the broad ligament. Each ovary was enclosed partially in an ovarian bursa and the distance between the two ovaries was about 2 cm (Figures 7 & 8).

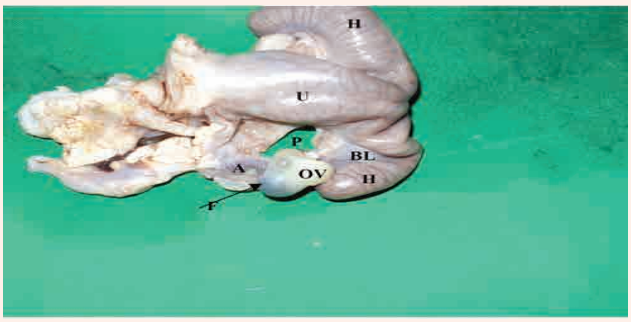

Figure 7: Photograph of the reproductive system in a female foetus during the third trimester (88 cm CVRL, 305.9 days old foetus) showing a large atretic vesicular follicles (F),in the surface of the ovary (OV), the proper ovarian ligament (P), the broad ligament (BL), the uterine horn (H), the uterus (U) and the ovarian artery (A).

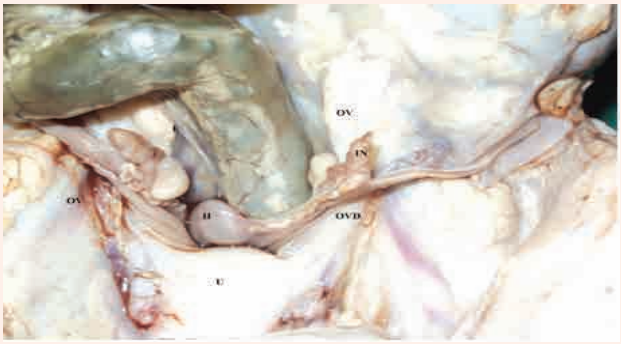

Figure 8: photograph of ventro–dorsal view in abdomino-pelvic region of a female foetus during the late stage of the third trimester (110 cm CVRL, 366 days old foetus). Showing the position of the ovary (OV) and the relation between the ovary and uterine horn (H). Note the follicle (F), the oviduct (OVD), the infundipulum (IN) and the uterus (U).

In 119 cm CVRL (390.6 days) foetus, the ovary had a bunch of grapes appearance and contained a large number of preovulatory follicles (about 27 follicles) bulging from the surface of left ovary. The ovaries that contained large vesicular follicles were only found in the foetuses at the third trimester as shown in Table 1. The dimensions of the foetal ovary increased with advancing development as shown in Tables 1 & 2.The length of the right ovary varied between 0.9 and 1 cm with an average of 0.96 cm, while the length of the left ovary ranged between 1 and 2 cm with an average of 1.3 cm. The width of the right ovary ranged between 0.4 and 1.2 cm with an average of 0.58 cm, while the width of the left ovary ranged between 0.4 and 1 cm with an average of 0.66 cm. The thickness of the right ovary varied between 0.3 and 0.5 cm with an average of 0.34 cm, while the thickness of the left ovary varied between 0.3 and 0.5 cm with an average of 0.42 cm. The weight of the left ovary ranged between 0.10 and 0.90 gm with a mean of 0.35 ± 0.07 gm, while the weight of the right ovary ranged between 0.10 and 0.60 gm with mean 0.26 ± 0.05 gm.

Table 1: Showing the number and sites of vesicular preovulatory follicles during third trimester of foetal ovaries.

A N	CVRL	Age in day	N. POF left ovary	N. POF right ovary	Side of POF
1	85	297.8	1	3	Left and right
2	88	305.9	1	2	Left and right
3	98	333	2	-	Left only
4	100	338.8	-	1	Left and right
5	101	341.5	2	1	Left and right
6	104	349.7	2	7	Left and right
7	104	349.7	2	1	Left and right
8	110	366	-	2	Right only
9	119	390.6	27	-	Left and right

AN=Animal Number, CVRL=Curved Crown Rump Length, N. POF=Number of preovulatory Follicles.

Table 2: Showing the dimensions of the ovary per cm during development.

AN	CVRL	Right ovary			Left ovary		
		Length	Width	Thickness	Length	Width	Thickness
1	8.4	0.3	0.1	0.1	0.3	0.1	0.1
2	15	0.4	0.2	0.2	0.4	0.2	0.2
3	24	0.6	0.4	0.4	0.6	0.4	0.4
4	28	0.7	0.3	0.3	0.7	0.3	0.3
5	41	0.8	0.4	0.4	0.8	0.4	0.4
6	78	0.9	0.5	0.3	1	0.5	0.3
7	83	1	0.4	0.3	1	0.5	0.4
8	89	1	0.5	0.3	1	0.5	0.3
9	104	1	1.2	0.5	2	0.9	0.5
10	114	0.9	0.4	0.3	1	0.4	0.4
11	119	-	-	-	1.8	1	0.5

Table 3: Showing the average dimensions of the ovary during different gestational period.

Gestational period	Right ovary			Left ovary		
	length	width	thickness	Length	width	thickness
first	**0.43**	**0.23**	**0.23**	**0.34**	**0.23**	**0.23**
second	**0.75**	**0.35**	**0.35**	**0.75**	**0.35**	**0.35**
third	**0.96**	**0.58**	**0.34**	**1.3**	**0.66**	**0. 42**

Volume

It was so difficult to measure the volume of the ovary during the early stages of development by the water displacement method because the organ was very small. The volume of the left ovary varied from 0.00 ml in the 33 CVRL and 1.00 ml.

Table 4: Showing the volume of the left and right ovaries /ml^3.

AN	CVRL	A I D	LOV	ROV
1	33.3	156.5	0	0
2	39.3	172.9	0.1	0.1
3	43.3	183.9	0.1	0.1
4	48	196.7	0.1	0.1
5	49	199.4	0.1	0.1
6	59	226.7	0.1	0.1
7	64	240.4	0.2	0.2
8	65	243	0.2	0.2
9	72	262	0.2	0.2
10	75.5	271.8	0.4	0.3
11	78	278.7	0.2	0.2
12	83	292	0.2	0.2
13	85	297.8	0.3	0.3
14	88	305.9	0.7	0.4
15	89	308.7	0.2	0.2
16	90	311	0.2	0.2
17	90.3	312	0.2	0.2
18	93	319.6	0.3	0.3
19	101	341.5	1	0.9
20	103.5	348	0.2	0.2
21	104	349.7	0.5	-
22	104	349.7	0.2	0.2
23	110	366	0.2	0.2
24	114	377	0.2	0.2
25	119	390.6	1	-

Table 5: Showing the minimum, maximum and mean of the ovarian volume.

volume	minimum	maximum	mean
ROV	0	0.9	0.20 ± 0.03
LOV	0	1	0.26 ± 0.05

AN=Animal Number, CVRL=Curved Crown Rump Length, AID=Age in Day, ROV=Right Ovary Volume, LOV=Left Ovary Volume.

Discussion

Abdel Hafez [14] suggested that, in 19 cm CVRL about (117) days old foetus, the mesonephroi disappeared completely. In the present study, in (22 cm CVRL) about (126 days old foetus), the regressing mesonephros disappeared completely on the left side, while in the right side it appeared like a small prominence in the caudal pole of the right metanephros. This observation disagreed with [14]. The present study also, indicated that, the left ovary differentiates earlier than the right one and was separated from the mesonephros. This result may explin the increasing incidence of pregnancy in the left horn in adult camels than the right one and that the left ovary may be more active than the right ovary. El Wishy (1987) and Skidmore [5] suggested that, there is nearly equal activity between the right and the left ovaries in camel. Musa [1] stated that, the increased rate of pregnancy in the left uterine horn is due to the early embryonic death in the right uterine horn. The descent of the ovary is phenomenon which occurs in most animal species prenatally. In sow foetus, Patten (1948) mentioned that, the ovaries have peritoneal folds comparable to the mesenteries of intestinal tract. When these folds are stretched out, they allow the ovaries, uterine tubes and uterus to move caudally, laterally and somewhat ventrally. In the mare, Dyce et al. (1987) suggested that, the ovaries descend from where they were developed initially and they commonly lie in the dorsal part of the abdomen, cranio-ventral to the iliac wings, approximately in the plane of the 6th lumber vertebra. In the third month buffalo foetus, the ovaries are located just cranial to the anterior end of the differentiated müllerian duct and are attached to the caudo-lateral borders of the kidney (Ranjbar et al., 2007).

In camels, Abd El-Razik [11] stated that, the position of the ovary of the camel foetus varied according to the stage of development and the ovaries were firstly observed in the sublumbar region medial to the mesonephros in (5-9.5) cm curved crown rump length foetus. On reaching the (14.5) cm curved crown rump length, they are noticed on the visceral surface of the permanent kidney. The finding in the present study is in agreement with Abd El-Razik [11] who also stated that, by the end of the 4th month, the ovaries are still abdominal in position lateral to the lateral border of the kidney. During the 5th month of gestation, they approach the pelvic inlet and attain their final pelvic position on the 13th month of gestation at 120 cm curved crown rump length. The present study disagrees with Abd El-Razik [11] that in 4 month old foetus, the ovaries were observed ventral to the lateral border of the kidney and in fifth month of gestation the ovaries were situated cranial to the pelvic inlet at the level of 6th and 7th transverse processes of lumbar vertebrae. Abdel Hafez [14] stated that, the rapid backward movement of the ovaries during the early stage of development is due to the rapid growth of the body cavity and the traction of the ovary caudally by the gubernaculum ovarii. Moreover, the size, shape and location of the ovaries of the camel foetuses varied according to the stage of the prenatal development. In the present study, the caudal descent of the ovary may be due to an increase in the body cavity associated with the normal body growth. During the differentiation of the uterine horns and uterus, these structures, pulled with them the gubernaculum ovarii causing the traction of the ovary caudally and ventrally. Later, this peritoneal fold forms the proper ovarian ligament and round ligament of the uterus. The present study also showed that, the descent of the ovary occurred rapidly in the early stages than the late stages of development. Similar observations were reported by Abdel Hafez [14] and McGeady et al. (2006).

In the present study the shape of the foetal ovary changes with the stages of development. In the first trimester, the ovary has an oval, spherical or bean shape while in the second trimester, the ovary has a typical kidney shape or flat. During the third trimester the ovary has an irregular shape (triangular or as a bunch of grapes). Abd El-Razik [11] & Abdel Hafez [14] reported different shapes of camel foetus ovary ranging from oval, spherical or bean shaped. Abdel Hafez [14] has noticed flat irregular shapes during the late stages of pregnancy. The current observations are in agreement with Abd El-Razik [11] and Abdel Hafez [14]. The ovarian weight in buffalo foetus gradually increased from early pregnancy to the end of gestation reaching 0.92 gram in full term foetus (El-Ghannam and El-Naggar, 1984). In the present study the weight of the ovary in full term foetus is much heavier than what is reported by Abdel Hafez [14] and this may be due to the difference in breeds of camels. During the second trimester, the weight of both left and right ovaries ranged between 0.10 gram in (31) cm CVRL (150 days old foetus) and 0.20 grams in (59) cm CVRL (226.7 days old foetus), while in the third trimester the left ovary ranged between 0.10 gram in 75.5 cm CVRL (271.8 days old foetus) and 0.9 gram in 119 cm CVRL (390.6 days old foetus). The weight of the right ovary ranged between 0.10 gram in 75.5 cm CVRL (271.8 days old foetus) and 0.6 gram in 119 cm CVRL (390.6 days old foetus). Abdel Hafez [14] stated that, the weight of the ovary is about 0.009 gram in 10.5 cm CVRL and reached 0.58 gram in full term. The present study revealed that, the dimensions of both left and right ovaries during the first and second trimester are similar, while in the third trimester the left ovary showed higher dimensions than the right ovary, and this may be due to the presence of alarge number of antral follicles which increase secretion of hormones in the left ovary than the right ovary; the secretion of hormones help in the development of the preantral follicles to antral follicles.

Conclusion

a. The development of the camel foetal ovary is in general similar to the development of the other domestic mammal's ovary but with special features of its own..

b. Sexual differentiation into a female occurs during the first trimester at (4.5 cm

CVRL, about 77.8 day old foetus).

c. The descending of the ovary began at (8 cm CVRL, about 87.4 day old foetus from the level of (3-4) transverse lumber vertebrate and reached the level ventral to the pelvic inlet in full term foetus.

d. The antral follicles and the large vesicular follicles were observed during early and last stages of the first trimester respectively.

Acknowledgement

I would like to express my sincere thanks and gratitude to Professor Dfa,alla Ibrahim Osman for his paternal and continuous supervision during the study period and his helpful discussions. Thanks are extended to my friend Dr. Abdonasir Mohammed Adam Terab for his help and accommodation.

References

1. Musa BE (1979) Studies on the ovary of the camel (*Camelus dromedarius*). Sudan Journal of Veterinary Science and Animal Husbandry 20: 51-54.
2. Wardeh MF (2004) Classification of the dromedary camel. The Camel Applied Research and Developmental Netwark. (CARDN) 1: 1-135.
3. Novoa C (1970) Reproduction in camelidae. Journal of Reproduction and Fertility 22: 3-20.
4. Sghiria A, Driancourt MA (1999) Seasonal effects on fertility and ovarian follicular growth and maturation in camels (*Camelus dromedaries*). Journal of Animal Reproduction Science 55: 223-237.
5. Skidmore JA, Adam GP (2000) Anatomy of the camel reproductive tract. International Veterinary Information Service. Ithaca, New York USA.
6. El Wishy AB (1988) A study of the genital organs of the female dromedary (*Camelus dromedarius*). Journal of Reproduction and Fertility 82: 587-593.
7. Skidmore JA (2005) Reproduction of dromedary camel: An update. Journal of Animal Reproduction 2: 106-171.
8. Rodger RJ, Irving Rodger HF (2010) Morphological classification of bovine ovarian follicles. Reproduction 139: 309-318.
9. Shehata R (1994) Medullary tubes in the ovary of camel and the other mammals. Veterinary Record 76: 750-753.
10. George AN, Fahmy MFA (1966) Histological study of the developing ovary of the dromedary (*Camelus dromedarius*). Journal of Veterinary Science 3: 93-100.
11. Abd El Razik MMA (1984) Some studies on the prenatal development of the ovary of one humped camel (*Camelus dromedarius*). Ph. D thesis, Faculty of Veterinary Medicine, Cairo University, Egypt.
12. Mohammed AY (1996) Morphological studies on the ovary of one humped camel (*Camelus dromedarius*). M.V.Sc. Thesis. Faculty of Veterinary Medicine, University of Khartoum, Sudan.
13. El Sharapy AA (1997) The characterization of the camel embryos for determination of the end of embryonic period. External features and internal. Morphogenesis. Journal of Veterinary Science 13: 485-500.
14. Abdel Hafez EW (2004) Histomorphological studies on the development of the ovary of one humped camel. Ph. D. Thesis, University of Assiut, Faculty of Veterinary Medicine, Egypt.
15. Sakai T (1955) Studeis of the development of the embryonic ovary in swine, cattle and horse. Japan Journal of Veterinary Research 3: 183-198.
16. El Ghannam F, El Naggar MA (1974) The prenatal development of buffalo ovary. Journal of Reproduction and Fertility 41: 479-483.
17. Sumts MS, Benzuidenhot AJ (1987) Anatomy of the dromedary. Carledonpress. Oxford, England.
18. Ali S (2006) Studies on ovarian follicular morphology, serum biochemistry and hormonal profiles in female camel (*Camelus dromedarius*) during the low and the peak breeding seasons. Ph.D Thesis, Faculty of Veterinary Science. University of Agriculture, Pakistan.
19. El Wishy AB, Himeida NA, Omer MA, Mobarak AM, El Sayed MAI (1981) Functional changes in the pregnant camel with special reference to foetal growth. British Veterinary Journal 137: 527-537.
20. Baker TG, Neal P (1974) Oogenesis in human foetal ovaries maintained in the organ culture. Journal of Anatomy 117: 591-604.
21. Beg MA, Meria C, Bergfelt DR, Ginther OJ (2003) Role of eostradiol in growth of follicles and follicle deviation in heifers. Reproduction 125: 847-854.
22. Ben Or S (1963) Morphological and functional development of the ovary of the Mouse I. Morphology and histochemistry of the developing ovary in normal conditions and after FSH treatment. Journal of Embryology Experimental and Morphology 11: 1-11.
23. Bielańska Osuchowska Z (2006) Oogenesis in big ovaries during the prenatal period: Ultrastructure and morphometry. Reproductive Biology 6: 161-193.
24. Black JL, Erickson BH (2005) Oogenesis and ovarian development in the prenatal pig. American Journal of Anatomy 161: 54-55.
25. Bulmer D (1964) The histochemical distribution of certain ovarian enzymes. Journal of Anatomy 98: 27-36.
26. Buruno JB, Celestino JJH, lima Verde IB, Lima LF, Matos MHT, et al. (2009) Expression of vascular endothelial growth factor (VEGF) receptor in goat ovaries and improvement of *in vitro* caprine prenatal follicle survival and growth with VEGF. Reproduction, Fertility and Development 21: 679-687.
27. Byscov AG, Moore SL (1973) Follicle formation in the immature mouse ovary: The role of the rete ovarii. Journal of Anatomy 116: 207-217.
28. De Bruin JB, Nikkels PGJ, Bruinse HW, Van Haaften M, Looman CWN, et al. (2001) Morphometry of the human ovaries in normal and growth restricted fetuses. Early Human Development 60: 179-192.
29. Fortune JE (1994) Ovarian follicular growth and development in mammals. Biology of Reproduction 50: 225-232.
30. Fouquet JQ, Dang DC (1980) A comparative study of the development of the foetal testis and ovary in the monkey (*Macaca fascicularis*). Reproduction, Nutrition and Development 20: 1439-1459.
31. Kurilo LF (1980) Development of the human ovary in the prenatal period. Arch Anatomy, Histology and Embryology 79: 73-79.
32. Kurilo LF, Tepliakova NP, Lavrikova GV (1987) Development of ovaries in bovine foetuses. Ontogenez 18: 500-506.
33. Madekurozwa MC, Kimaro WH (2006) A Morphological and imunohistochemical study of healthy and atretic follicles in the ovary of the sexually Immature ostrich (*Struthio camelus*). Anatomia, Histologia and Embryologia 35: 253-258.
34. Mahdi D, Khelili K (2010) Circulating gonadotropins levels and contribution of different large antral follicles to isofolliculia in sheep. Animal Reproduction Science 118: 25-31.
35. McNatty KP, Smith P, Hudson NL, Heath DA, Tisdall DJ, et al. (1995) Development of the sheep ovary during foetal and early neonatal life and the effect of fecundity genes. Journal of Reproduction and Fertility Supplement 49: 132-135.
36. Mohammedpour AA (2007) Comparative histomorphological study of the ovary and ovarian follicles in Iranian Lori Bakhtiari sheep and native goat. Pakistan Journal of Biological Sciences 10: 673-675.
37. Nawar SMA, Abul Fadle A, Mahmoud SA (1987) Studies on the ovarian activity of the dromedary (*Camelus dromedarius*). Zeitschrift Fürmikroskopisch Anatomische Forschung 92: 385-408.
38. Sckwartz HJ, Dioli M (1992) The one humped camel in Eastern Africa. Verlag Josef Margraf Scientific books. Germany.
39. Zamboni L, Bezard J, Mauleon P (1979) The role of the mesonephros in the development of the sheep foetal ovary. Annales De Biologie Animale, Biochimie Et Biophysique 19: 1153-1178.