



CORPUS PUBLISHERS

Open Access Journal of Dental and Oral Surgery (OAJDOS)

Volume 2 Issue 2, 2021

Article Information

Received date : October 03, 2021

Published date: October 27, 2021

*Corresponding author

Dr.Hemant Baonerkar, MDS Oral
Maxillofacial Surgery, PhD OMFS
Research Scholar Mumbai, India

Keywords

Radicular Cyst; Bone Graft;
Deminerlized Freeze Dried Bone
Allograft (DFDBA); Healing; Enucleation;
Gray Scale Histogram

Distributed under Creative Commons
CC-BY 4.0

Research Article

Radiographical Comparison of Post Surgical Bone Healing Following Enucleation of Radicular Cyst with and without Bone Graft

Dr.Hemant Baonerkar*

MDS Oral Maxillofacial Surgery, PhD OMFS Research Scholar Mumbai, India

Abstract

Odontogenic jaw cysts are common lesions in the oral and maxillofacial region. Enucleation and Bone grafting is the treatment of choice for large jaw cysts. After enucleation of jaw cyst, the bone defect is generally left for the spontaneous bone healing which will take time for complete bone healing. Replacement of jaw bone defect is one of the challenges faced by oral and maxillofacial surgeons since long time. For treating such defects bone grafting is an ideal treatment option. Bone grafting after removal of different pathologic defects was evaluated by many authors, but same study was not reported for exclusively for radicular cysts. In the present study, Deminerlized Freeze Dried Bone Allograft (DFDBA) was placed after enucleation of the radicular cyst and healing was evaluated on the gray scale histogram study up to 6-month post-operative period. This method first time used for exclusively for the Radicular cysts.

Introduction

“Healing is a matter of time, but sometimes also is a matter of Opportunity” - Hippocrates (460-377 BCE) [1]. Human bone is characterized by the unique ability to regenerate its original structure after defects or fractures through a programmed sequence of maturation steps closely resembling the pattern of bone development and bone growth [2]. The art of repairing a bone defect has been accomplished and refined by man for thousands of years. Examination of a skull from 2000 BC uncovered evidence of healing around a 7-mm defect repaired with a piece of animal bone. Surgeon Job van Meekeren heralded the modern era of bone replacement in 1668 when he successfully performed the first heterologous graft by inserting the fragment of a dog skull into the skull of an injured soldier. In 1820, a German surgeon by the name of Philips von Walter performed the first autologous graft, replacing a cranium fragment after trephination [3]. Bone grafting is done for accelerated bone healing in surgical field by the surgeons [4]. There are many applications for using bone and bone substitutes in surgery, including restoring form and function to the skeletal structure, providing stabilization, and enabling aesthetic modifications [5]. Bone substitutes are being increasingly used in craniofacial surgery. This is due to their ease of use and handling, improved safety profiles, operative cost and time advantages, and adaptability to a variety of clinical challenges [3].

In this era of 21st century, it has become necessary for oral and maxillofacial surgeons to retain or regain the bone lost secondary to oral surgical procedures. The bone-grafting process is not a new procedure in the field of oral and maxillofacial surgery. Surgeons have been performing autologous grafts to the cranial facial region for many years [5]. Radicular cyst is the most common cystic lesion in the jaws. Recent study shows that 42%-44% of all periapical lesions are radicular cysts [7-10]. Enucleation and Marsupialization are two surgical treatment methods for radicular cyst [11-13]. Size and location of a cyst is considered before planning the treatment of a radicular cyst, but enucleation and bone grafting are the treatment of choice for large jaw cysts [6]. Now a days there are many bone replacement materials are available, like allograft, xenograft, alloplast, but autologous bone graft said to be gold standard for it [5]. Autologous bone graft harvesting procedure has many disadvantages. Allogenic bone grafts have now been used for more than 50 years in orthopaedics and maxillofacial surgery. Recently allogenic bone graft has gained wider attention in the scientific and clinical communities, and some promising results have been achieved, in terms of generating excellent quantity and quality of bone. It has excellent osteoconductive and osteoinductive properties [5]. In this present study, Radiographical comparison of post-surgical bone healing has been done following enucleation of radicular cyst with and without bone graft. For bone grafting, Deminerlized Freeze Dried Bone Allograft (DFDBA) has been used, and bone healing is measured by calculating bone density on gray level histogram [4,14].

Material and Methods

The study samples were selected from the population of subjects who reported to the department of Oral and Maxillofacial Surgery. On the basis of case history, clinical examination and radiographical features, the subjects with provisional diagnosis of radicular cyst were selected for the study. Final diagnoses were then confirmed with histopathology report.

Sample size:

A total of 20 cases of radicular cysts in the age group of 20 to 50 years were selected for the study.

Cases were divided into 2 groups.

Group 1 - Group of patients with radicular cyst for which enucleation without bone graft placement was done. (10 cases)

Group 2 - Group of patients with radicular cyst for which enucleation with bone graft (i.e. DFDBA) placement was done. (10 cases)

Inclusion criteria

- a. Patients with Radicular cyst.
- b. Patients in the age group of 20 to 50 years.

Exclusion criteria

- a. Medically compromised patients.

Materials

Demineralized Freeze Dried Bone Allograft (DFDBA) material was used for bone grafting in group 2 cases. Particle size-500 to 1040 microns.

Method

- i. Patients satisfying the inclusion criteria were selected for the study.
- ii. Before the surgical procedure, routine blood investigation and pre-operative radiographs were taken. Well informed written consent was also obtained for the surgical procedure. After following aseptic surgical protocol, all cases were done under local anesthesia. The flap design was marked according to the location of radicular cyst than full thickness mucoperiosteal flap was reflected. Overlying cortical bone was removed and pathologic tissue was exposed. With the help of curettes enucleation of cystic tissue was done. Before initiating the surgical procedure Demineralized freeze dried bone allograft was well soaked in sterile saline to make a paste like consistency.
- iii. Cases were randomly divided in the study groups.
- iv. No bone graft was placed in bony defect for Group 1cases.
- v. The bone paste was placed in bony defects for Group 2 cases.
- vi. The flap was then repositioned and sutured with the help of 3-0 black silk or vicryl suture material.
- vii. Post-surgical instructions and medications were given to the patients.
- viii. Radiographs were taken on immediate postoperatively and after 1month, 3months, 6 months follow up period post-operative.
- ix. Optical densities of bony defects were recorded during follow up on the radiographs.
- x. Relative bone density of the pixels of bone defect and area around them were measured with the help of computer software Adobe photoshop v.8 (on grey scale of 255 tonalities) using gray level histogram [4,14].
- xi. Index of relative bone healing were calculated with help of readings of pixel density of bone defect and area around them to evaluate bone healing progress (Figures 1-4).

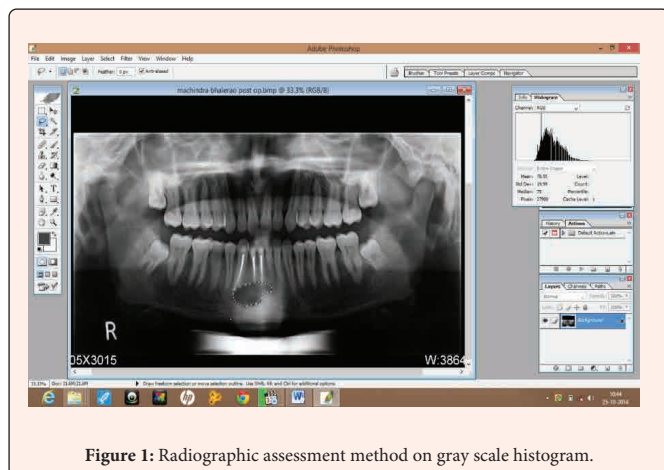


Figure 1: Radiographic assessment method on gray scale histogram.

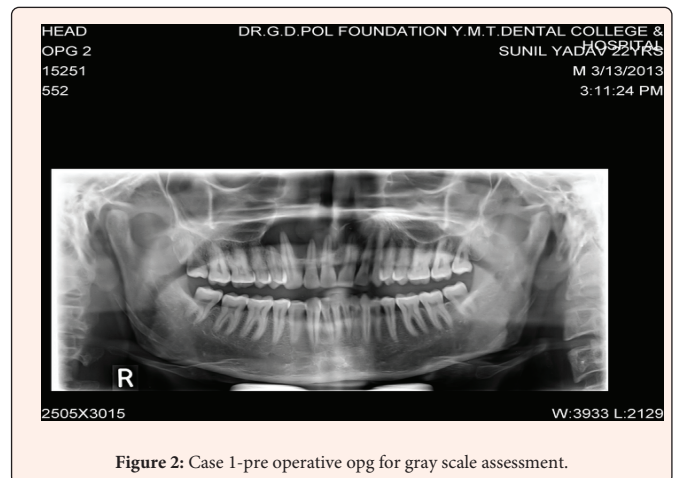


Figure 2: Case 1-pre operative opg for gray scale assessment.

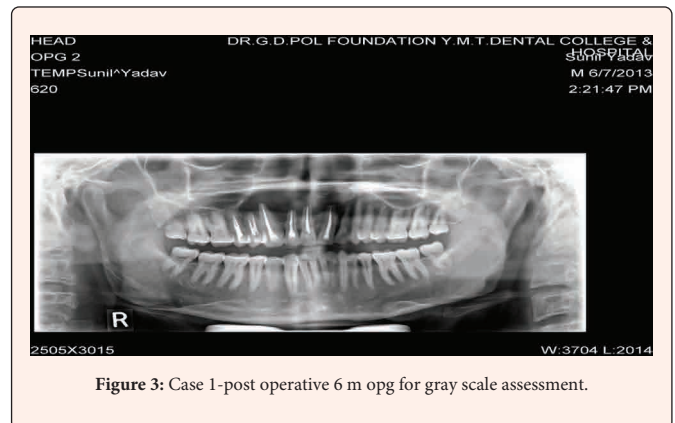


Figure 3: Case 1-post operative 6 m opg for gray scale assessment.

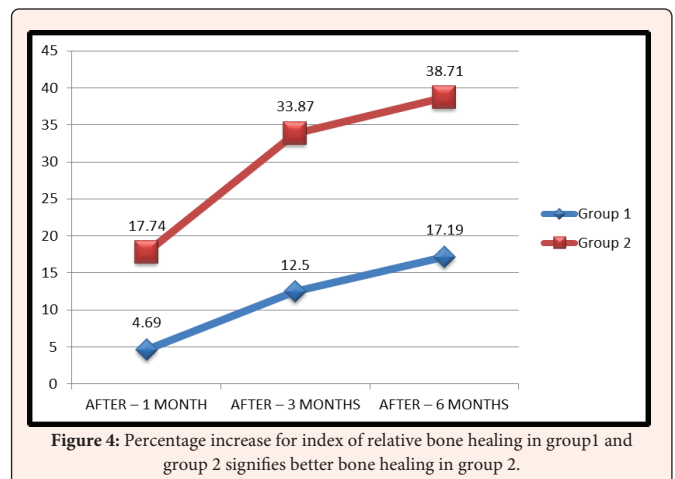


Figure 4: Percentage increase for index of relative bone healing in group1 and group 2 signifies better bone healing in group 2.

Evaluation Criteria

For radiographic assessment of bone healing following parameters were used.

All patients were evaluated on immediate post-operative day, after 1 month, 3 months and 6 months post-operatively for:

- i. Bone Density of Bony Defect.
- ii. Bone Density of Surrounding Bone.



iii. Index of relative bone healing.

On Radiographs, Relative bone density of the pixels of bone defect and area around them were measured with the help of computer software Adobe photoshop v.8 (on gray scale of 255 tonalities) using gray level histogram [4,14].

Index of relative bone healing was calculated by the following formula14:

Index of relative bone healing (I) = Bone Density of Bony defect/ Bone Density of surrounding bone

For the radiographic assessment of bone healing, all radiographs were transferred to the computer software Adobe photoshop v.8. Bone density was measured on the radiographs through a grayscale histogram of 256 tonalities. Areas of pixels were selected both on the lesion regions and healthy bone from the symmetrical regions of the cysts. Denser parts had higher tonality values. The difference between healthy bone and pathologic bone tonalities were calculated on the radiographs taken at different times. The decrease in this difference, along with tonal increase in the operation site (increased radioopacity) at the 1st, 3rd and 6th months post operatively, indicated an increase in the bone density at the surgical site, suggestive of bone healing progress. The calculated values were evaluated and tabulated for statistical evaluation.

Observations

To evaluate bone healing, bone density of bony defect, bone density of surrounding bone and index of relative bone healing were calculated on radiographs (Table 1).

Results

Table 1: Index of relative bone healing.

Table with 2 main sections: 'Index (I) of Relative Bone Healing for Group 1' and 'Index (I) of Relative Bone Healing for Group 2'. Each section has columns for Case No., Immediate Post Operative, After - 1 Month, After - 3 Month, and After - 6 Month.

The samples were then subjected to statistical analysis using ANOVA test, t test and Tukey's multiple comparison test. The age of the patients varied from 22 to 49 years in both group with the mean age of 36 years in group-1 and 30.9 years in group-2 respectively. In the total 20 cases, 15 were male patients (75%) and 5 were female patients (25%) included. There were obvious male predilections with 8 patients (80%) in group 1 and 7 patients (70%) in group 2 than female cases, 2 patients (20%) in group 1 and 3 patients (30%) in group 2. In the total 20 cases of radicular cyst, 15 cases were seen in maxilla (75%) and 5 cases were seen in mandible (25%). In group-1, total 9 cases were seen in maxilla (90%) while only 1 case was seen in mandible (10%) and in group-2, total 6 cases were seen in maxilla (60%) while 4 cases were seen in mandible (40%). There were clear predominant involvement of maxillary jaw (75%) was seen. Table and graph shows comparison between groups for values of bone density of bony defect. In group 1, there is percentage increase of 5.37% after 1 month, 17.86% after 3 month and 28.27% after 6 month comparing from immediate post-operative values. In group 2, there is percentage increase of 19.53% after 1 month, 43.48% after 3 month and 60.22% after 6 month comparing from immediate post-operative values. Table and graph shows comparison between groups for values of index of relative bone healing. In group 1, there is percentage increase of 4.69% after 1 month, 12.5% after 3 months and 17.19% after 6 months comparing from immediate post-operative values. In group 2, there is percentage increase of 17.74% after 1 month, 33.87% after 3 months and 38.71% after 6 months comparing from immediate post-operative values. p-value for Index (I) of Relative Bone Healing is less than that of 0.05 indicates significance of difference and from means we can conclude that the average value Index (I) of Relative Bone Healing is significantly more for group 2 than that of group 1 at 6-month (Table 2).

Table 2: Descriptive Statistical data for index of relative bone healing in group 1 vs group 2.

Table with 7 columns: Group 1, Group 2, Mean, SD, % Increase. Rows include Immediate Post Operative, After - 1 Month, After - 3 Months, and After - 6 Months.

Discussion

The results of present study revealed extremely good results for us. In this study, we did not come across infection, graft rejection, inflammatory or other complications in any cases. Different parameters were compared to achieve aims and objectives of study. In study group (group-2) we found statistically significant change in the bone density of bony defect (p<0.05) and gained 19.53%, 43.48% and 60.22% increase in bone density of bony defect for 1st, 3rd and 6th months post-operative radiographs respectively when compared with immediate post-operative values. Whereas control group (group 1) showed 5.37%, 17.86% and 28.27% changes in bone densities for 1st, 3rd and 6th months post-operative radiographs when compared immediate post-operative values. This result is similar to result given by Bonder et al in 1996 that, defect grafted with DFDBA reached density levels to doubles in time equal to those of the non-grafted defect.6 (60.22% vs 28.27% after 6 months.) in this study percentage of change in mean value of bone density (without bone grafting) after 6 months is similar (28.27% in group 1) to study conducted by Shokier and khalifa10 in 2009. (32.3% in maxilla and 33.3% in mandible.) [10]. On gray scale histogram values, index of relative bone healing shows more accurate bone healing pattern. In present study the index of relative bone healing is also significantly increased in group 2 than group 1. In study group (group-2) we found statistically significant change (p<0.05) in the index of relative bone healing and gained 17.74%, 33.87% and 38.71% increase in index of relative bone healing for 1st, 3rd and 6th month post-operative values respectively when compared with immediate post-operative values. whereas control group (group 1) showed 4.69%, 12.5% and 17.19% changes in the index of relative bone healing for 1st, 3rd and 6th month post-operative radiographs when compared with immediate post-operative values. Despite of minimised errors originating from radiographic technique, digitalization of radiograph and density recording, there were some changes in values of bone density of surrounding bone observed. But in all our statistical analysis there is no significant difference observed in values of bone density of surrounding bone.



When compared individual groups at different time intervals, according to ANOVA test and Tukey's test results, in group 1 there is significant difference observed ($p < 0.05$) at interval of immediate post-operative, after 1-month and after 6-months in bone density of bone defect values. For all other comparison the difference is not significant in group 1. In group 2 there is significant difference observed ($p < 0.05$) at interval of immediate post-operative and 6-months for bone density of bony defect and the immediate post-operative and 3-months & 6-months for index of relative bone healing values. For all other comparison the difference is not significant in group 2. According to t-test at all different time intervals there is no significant difference seen, when compared between groups for bone density of bony defect and bone density of surrounding bone values. But for index of relative bone healing values, there is significant difference observed ($p < 0.05$) after 3 months and 6 months, when compared between groups. So it was concluded that the average values of index of relative bone healing is significantly more for group 2 than that of group 1 at post-operative 3-months and 6-months intervals. The results revealed that there is increase in bone density of defect during follow up period indicating progressive bone healing, which is similar to study given by Pradel et al in 2006 and Shokier and Khalifa¹⁰ in 2009. Present Study also indicates that grafting of DFDBA to radicular cyst enhances bone formation, with similar results given by Bodner et al in 1996 [6].

Conclusion

Previously, many studies were done for spontaneous bone healing in jaw cysts, but there were no studies comparing bone healing after enucleation of only radicular cyst with and without bone graft. On the basis of statistical analysis there was significant difference observed ($p < 0.05$) in average of index of relative bone healing after 3 months and 6 months, when compared between groups. Which concludes that the average value of index of relative bone healing is significantly more for group 2 than that of group 1, suggesting that the enhanced bone healing in bony defect in group 2 is more compared to group 1, after 3 months and 6 months. Study also showed that defects grafted with DFDBA reached density levels to double compared to those with non-grafted defects in same time duration. (60.22% vs 28.27% after 6 month.). In this study, on the basis of radiographic values we can conclude that, treatment of radicular cyst after enucleation with bone grafting (DFDBA) gives enhanced bone healing than that of without bone grafting cases.

Acknowledgment

We like to give thanks to late DR. M D Shringarpure sir for his valuable guidance to plan this study.

References

1. Yapijakis C (2009) Hippocrates of Kos, the father of clinical medicine, and Asclepiades of Bithynia, the father of molecular medicine. Review. *In Vivo* 23(4): 507-514.
2. Ettl T, Gosau M, Sader R, Reichert TE (2012) Jaw cysts - filling or no filling after enucleation? A review. *J Craniomaxillofac Surg* 40(6): 485-493.
3. Pryor LS, Gage E, Langevin CJ, Herrera F, Breithaupt AD, et al. (2009) Review of bone substitutes. *Craniomaxillofac Trauma Reconstr* 2(3): 151-160.
4. Pradel W, Eckelt U, Lauer G (2006) Bone regeneration after enucleation of mandibular cyst: Comparing autogenous grafts from tissue-engineered bone and iliac bone. *Oral Surg Oral Med Oral Pathol Oral Radiol Endod* 101(3): 285-90.
5. Kao ST, Scott DD (2007) A review of bone substitutes. *Oral Maxillofac Surg Clin North Am* 19(4): 513-521.
6. Bodner L (1996) Effect of decalcified freeze-dried bone allograft on the healing of jaw defects after cyst enucleation. *J Oral Maxillofac Surg* 54(11): 1282-1286.
7. Śmieszek WJ, Koszowski R, Pająk J (2010) Comparison of postoperation bone defects healing of alveolar processes of maxilla and mandible with the use of Bio-Gen and Bio-Oss. *J Clin Exp Dent* 2(2): e60-66.
8. Shear M, Speight P (1992) *Cysts of the Oral Regions*. 3rd ed, Blackwell Munksgaard, Oxford, UK
9. Shear M, Speight P (2004) *Cysts of the Oral Regions*. Fourth Ed, Blackwell Munksgaard, Oxford, UK.
10. Shokier HM, Khalifa GA (2009) Assessment of bone healing in large bony defects after enucleation of jaw cysts without using any graft material Using direct digital radiography and CT scan (clinical study). *Cairo Dental Journal* 25(1): 35-42.
11. Shafer G, Hine K, Levy M (2006) *Shafer's Textbook of Oral Pathology*. In: Rajendran R (Ed.), *Cysts and tumors of odontogenic origin*. Fifth Ed, Noida, India.
12. Solar K, Sanded S, Grgurević E (2001) Surgical Treatment of Large Mandibular Cysts. *Acta Stomat Croat*, pp. 253-257.
13. Torres LD, Segura JJ, Rodríguez CA, Llamas JM, Gutiérrez JL (2011) Treatment of a large maxillary cyst with marsupialization, decompression, surgical endodontic therapy and enucleation. *J Can Dent Assoc* 77: b87.
14. Ihan HN, Miljavec M (2008) Spontaneous bone healing of the large bone defects in the Mandible. *Int J Oral Maxillofac Surg* 37(12): 1111-1116.