CORPUS PUBLISHERS

Open Access Journal of Dental and Oral Surgery (OAJDOS)

ISSN: 2833-0994

Volume 3 Issue 4, 2022

Article Information

Received date : October 11, 2022

Published date: November 21, 2022

*Corresponding author

Carlos M Cobo Vázquez, Associate Dentist, Department of Stomatology and Dentistry, Gregorio Marañón University General Hospital, Spain

Keywords

Apicectomy; Apical Resection; Mineral Trioxide Aggregate; Endodontic Failure

Case Report

Apicectomy of Upper Lateral Incisor with Symptomatic Persistent Cystic Lesion Previously Treated with Nonsurgical Retreatment

Luis Alfredo Díaz Olivares[1], Carlos M Cobo Vázquez[2,3*], Esther Cáceres Madroño[4], Juan López Quiles[5] and Cristina Meniz García[5]

[1]*Oral Surgery and Implantology Master Student, Department of Clinical Specialities, Faculty of Dentistry, Complutense University of Madrid, Spain*

[2]*Associate Dentist, Department of Stomatology and Dentistry, Gregorio Marañón University General Hospital, Spain*

[3]*Associate Professor, Department of Clinical Specialities, Faculty of Dentistry. Complutense University of Madrid, Spain*

[4]*University Professor, Department of Clinical Specialities, Faculty of Dentistry Complutense University of Madrid, Spain.*

[5]*Titular Professor, Department of Clinical Specialities, Faculty of Dentistry, Complutense University of Madrid, Spain*

Summary

Endodontic failure caused by transportation, drilling, overfilling and failure to repair an injury apical sometimes lead to surgical therapy. With periapical surgery consisting of exposure of the apex, root resection and preparation of a cavity that is hermetically sealed, we will correct the persistent defects. The combination of this surgical technique with retrograde obturation provides high success rates. There are several widely used retrofilling materials, such as: IRM, Retroplast, SuperEBA or mineral trioxide aggregate (MTA) whick allow a retrograde sealing of the preparations.

A case of a patient with recurrent apical lesion, describes the surgical technique of apicectomy and retrograde filling to preserve an upper lateral incisor with failed root canal retreatment and symptomatic persistent apical lesion.

Introduction

Apical resection or apicectomy is removal of the cyst or infection at the dental root tip together with 1/3 of the bottom part of the dental root. It is a surgical treatment applied usually in case the non-surgical root canal treatment fails [1]. Several epidemiological studies have suggested that 33-60% of endodontically-treated teeth still presented the pictures of apical periodontitis [2]. The possible causes may be persistent primary infection, secondary infection after endodontic therapy, vertical root fracture or cemental tears [3]. Nonsurgical retreatment is preferable as the first choice for management of teeth with symptoms/signs, apical lesions and prior root canal treatment [5]. However, there were some limitations restricting the possibility of nonsurgical root canal retreatment, e.g., obstructed canal pathway, irretrievable materials within the root canal and persistent symptoms, which could not be resolved even after the meticulous performance of nonsurgical treatment, persistent pain or swelling/sinus tract even after endodontic treatment and re-treatment [2]. For above reasons, apical surgery can be conducted to preserve the affected teeth [4]. Endodontic microsurgery is characteried by suceess rates of 90%-94% after approximately 1-2 years of follow-up. while the long-term evidence is limited, the healing rate may decrease to 78%-81.5% after 5-10 years of follow-up [5]. The type of root-end filling material was the most commonly studied issue. The bioceramic cements played a major effect on the success of endodontic surgery, since the introduction of mineral trioxide aggregate (MTA), Biodentine and lastly the five mineral oxides (5MO) [6]. The aim of this case report was to expose the apical surgery to preserve an upper lateral incisor with failed root canal retreatment and symptomatic persistent cystic lesion.

Case Report

Case Presentation and Patient Information

A 23-year-old female patient was referred to Master of Oral Surgery and Implantology UCM. She reported that the root canal treatment was performed when she was 15 years old. Two months ago, root canal re-treatment was performed on tooth #22 but the patient kept feeling pain. The clinical examination revealed a positive response to percussion and digital palpation in the periapical region of #22 with no fistula. The intraoral examination did not show any caries or color alteration related to the respected tooth (Figure 1). The depth of its gingival pocket varied between 1 and 3 mm with various exploring locations and grade I mobility. Teeth #23–#24 were tested by the pulp vitality test (the cold test) performed by refrigerant gas (Endo-Frost Spray, Roeko®) and relative isolation using cotton rolls and a dental saliva ejector. Teeth #23 and #24 presented positive responses with characteristics of healthy pulp tissue. However, teeth #21-#22 had a negative response.

Figure 1: Intraoral image of anterior sextant.

Radiographic examination revealed a radiolucent circumscribed lesion around the periapical region of tooth #22 presenting features of periapical periodontitis (Figure 2).

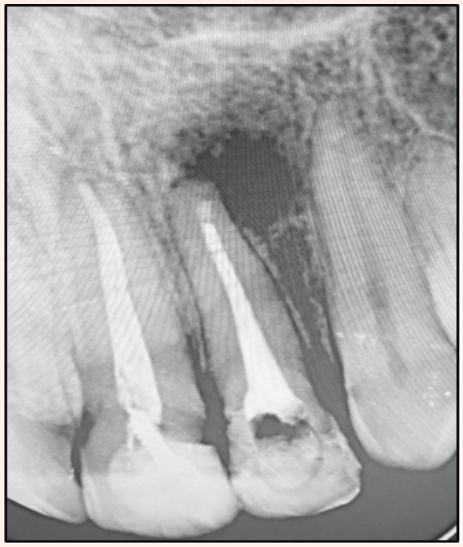

Figure 2: Periapical radiography of the periapical lesion of tooth #22.

The final diagnosis was symptomatic periapical periodontitis with radiolucent circumscribed lesion associated and the treatment plan was to perform and endodontic surgery (apicectomy), disinfect the periapical region and seal the root with MTA. Bone regeneration was not planned.

Therapeutic Interventions

The apicoectomy surgery was performed under local anesthesia using one anesthetic tube (4% articaine with epinephrine 1: 100,000), with intraoral access to the lesion achieved via intrasulcular incision of the buccal region from teeth 21 to 23 (Figure 3). After detachment of the flap, the perforation was clear, and a minimum osteotomy was performed to obtain a surgery window using a surgical carbide drill (Figure 4). The apical third of the root was sectioned using a surgical bur under intense irrigation with sterile saline solution, and then, the root canal was retroinstrumented by ultrasonic diamond tip. The cystic lesion was completely removed after an exhaustive curettage of the bone defect (Figure 5). Then, the root canal was retrofilled with MTA mixed with anesthesia (Figure 6-8). Finally, the flap was repositioned, followed by intrasulcular suturing with 4-0 silk thread (Silkam®) (Figure 9). The medication schedule was Amoxicilline 750 mg 1 every 8 hours for 7 days and Dexketoprofen 25 mg 1 every 8 hours for 7 days. Postoperative periapical radiography was performed immediately after suturing (Figure 10).

Figure 3: Surgical window.

Figure 4: Osteotomy.

Figure 5: Cyst lesion removal.

Figure 6: MTA mixed with anesthesia.

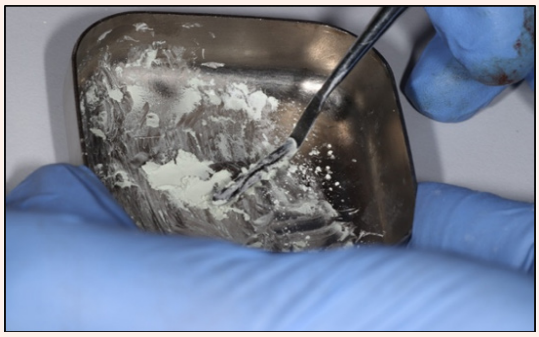

Figure 7: Ready-to-use

Figure 8: Root canal retrofilled.

Figure 9: Flap repositioned.

Figure 10: Postoperative periapical radiography.

The suture was removed ten days later, and the patient progressed well postoperatively without intercurrences (Figure 11).

Figure 11: Clinical image ten day later.

Follow-Up and Outcomes

Ten days later, the patient had no postoperative intercurrences and an intraoral evaluation was performed to investigate any hematoma or edema. The patient related a slight edema in the first two days following the surgery that disappeared posteriorly. No exudate was observed or related. The examinations noted an absence of symptoms, such as pain, swelling, trismus and the normal function of the tooth was preserved.

Discussion

Apicectomy is considered as the last resort to preserve natural teeth after the failure of endodontic treatment. The main goal of endodontic microsurgery is to create a tight seal in the root apex and thereby to prevent the occurrence of a pathway between the root canal system and peri-radicular tissues [7]. Regarding the follow-up period, surgical retreatment cases are prone to heal faster than nonsurgical ones [8]. Song et al. [9] demonstrated that the most relevant evidence concerning the healing process was obtained at the first-year post-surgery and that the variation in the clinical outcome between one- and four or more-years follow-up period was not significant. Hence, the one-year follow-up may be sufficient to predict long-term outcome of apicectomy [10]. Song et al. found the healing rate of 115 cases one and 4 years after endodontic microsurgery to be 87.8% and 91.3%, respectively, though the difference was not statistically significant [9]. The effect of the root-end filling material is one of the intraoperative key factors of apicectomy outcome. Endodontic microsurgery requires biocompatible materials such as IRM, Retroplast, SuperEBA, MTA, among others [11]. MTA has the ability to stimulate bone, dentin, and cementum formation, promoting

tissue regeneration (e.g., periodontal ligament and cementum) [12]. Von Arx et al. [13] also suggested that the most effective seal over a follow-up period of five years was achieved with MTA. However, Zhou et al. [14] found no significant difference in apicectomy clinical outcomes when comparing MTA and BP-RRM, with both showing favorable biocompatibility, no cytotoxic effects and similar sealing performance.

One of the limitations of the present case report is the fact that follow-up was based on the use of 2-dimensional periapical radiographs. In this regard, cone-beam computed tomography may soon prove to be an excellent alternative for assessing healing in endodontic microsurgery in 3 dimensions [5] since it has been shown to be more sensitive and specific than periapical radiographs in evaluating radiolucent periapical zones [15]. Independently of all other factors, the results exposed in the literature suggest that the duration of follow-up is a key parameter for the final evaluation. Regarding the success rate of endodontic microsurgery, several studies recorded no statistically significant differences in relation to patient age or gender, previous radiographic lesion size, the type of tooth, the presence of a post, the type of restoration, or the apical extent of previous root canal filling. Interproximal bone level is considered a variable of clinical importance, which could have a guide value when making a decision whether or not to carry out conservative surgical treatment.

Conclusion

Nonsurgical retreatment is preferable as the first choice for management of teeth with symptoms/signs, apical lesions and prior root canal treatment. In cases of symptomatic persistent apical lesion, is possible to achieve improvement in periradicular tissues as in the case reported with apicectomy. To make this possible, it is necessary to resort to surgical techniques and to use retrograde filling materials with ideal characteristics to stimulate the healing of affected tissues. In conclusion, apical surgery is suggested, followed by retrograde filling with MTA in these cases.

References

1. Yasin ES, Altay H, Hasanoglu EN (2019) The evaluation of apicectomy without retrograde filling in terms of lesion size localization and approximation to the anatomic structures. Med Oral Patol Oral Cir Bucal 24(2): e265-270.
2. Wan CL, Yuan LL, Yi-Ling Tsai et al. (2019) Outcome assessment of apical surgery. A study of 234 teeth. Journal of the Formosan Medical Association 118(6): 1055-1061.
3. Çalışkan MK, Kaval ME, Tekin U, Unal T (2016) Radiographic and histological evaluation of persistent periapical lesions associated with endodontic failures after apical microsurgery. International Endodontic Journal 49(11): 1011-1019.
4. Song M, Jung IY, Lee SJ, Lee CY, Kim E (2011) Prognostic factors for clinical outcomes in endodontic microsurgery: a retrospective study J Endod 37(7): 927e33.
5. Pallarés SA, Glera SP, Tarazona AB, Peñarrocha OD, Peñarrocha DM et al. (2022) Healing of 295 Endodontic Microsurgery Cases After Long-Term (5-9 Years) Versus Middle-Term (1-4 Years) Follow-up. Journal of Endodontics 48(6): 714-721.
6. Abu HA, Pereira SD, Regina GT, Barbosa AA, Rogerio PC, et al. (2020) Apicoectomy of Perforated Root Canal Using Bioceramic Cement and Photodynamic Therapy. International Journal of Dentistry 2020: 6677588.
7. Torul D, Kurt S, Kamberoglu K (2018) Apical surgery failures: Extraction or re-surgery? Report of five cases. J Dent Res Dent Clin Dent Prospects. Spring 12(2): 116-119.
8. Kvist T, Reit C (1999) Results of endodontic retreatment: A randomized clinical study comparing surgical and nonsurgical procedures. J Endod 25(12): 814-817.
9. Song M, Chung W, Lee SJ, Kim E (2012) Long-term outcome of the cases classified as successes based on short-term follow-up in endodontic microsurgery. J Endod 38(9): 1192-1196.
10. Sarnadas M, Marques J, Baptista I, Santos JM (2021) Impact of Periodontal Attachment Loss on the Outcome of Endodontic Microsurgery: A Systematic Review and Meta-Analysis. Medicina (Kaunas) 57(9): 922.
11. Song M, Jung IY, Lee SJ, Lee CY, Kim E (2011) Prognostic factors for clinical outcomes in endodontic microsurgery: A retrospective study. J Endod 37(7): 927-933.
12. Alghamdi F, Alhaddad AJ, Abuzinadah S (2020) Healing of Periapical Lesions After Surgical Endodontic Retreatment: A Systematic Review. Cureus 12(2): e6916.
13. Arx T, Jensen SS, Hänni S, Friedman S (2012) Five-year longitudinal assessment of the prognosis of apical microsurgery. J Endod 38(5): 570-579.
14. Zhou W, Zheng Q, Tan X, Song D, Zhang L, et al. (2017) Comparison of mineral trioxide aggregate and iroot bp plus root repair material as root-end filling materials in endodontic microsurgery: A prospective randomized controlled study. J Endod 43(1): 1-6.
15. Curtis DM, VanderWeele RA, Ray JJ, Wealleans JA (2018) Clinician-centered Outcomes Assessment of Retreatment and Endodontic Microsurgery Using Cone-beam Computed Tomographic Volumetric Analysis. J Endod 44(8): 1251-1256.